

# Precise Empirical Scleral contact lens fitting designing utilizing Profilometry

Kyriakos Telamitsi, BSc (Optics), Optometry, Contact Lenses Practitioner, FSLs, ISCLS

## Introduction

Over the last decade, scleral lenses have seen a large progression in the design based on better knowledge of the scleral shape. One of these new developments is the ability to design empirical scleral contact lenses. This method will help to reduce the chair time and reduce the number of refits. Previous studies showed an average number over 3 remakes. In Cyprus there is a high incidence of post-LASIK eyes showing ectasias and scleral lenses are an excellent choice.

## Method

A profilometer is needed for empirical fit in order to get enough information about the scleral shape. In this case, the Eye Surface Profiler or ESP (Eaglet Eye, Houten, NL) was used to take the measurements. It is possible to take a measurement of up to 20mm in diameter in a single shot with no stitching or data extrapolation. The ESP data was used to design a freeform lens SLC Adapta (MedLac, Avellino, IT).

## History

A 58-year-old female with previous history of refractive surgery for myopia larger than -20DS. The patient was referred through an ophthalmologist for specialty contact lenses. Her unaided visual acuity (VA) for OD is 1/10. The patient was already a spectacle wearer OD +3.00 -1.25x97, OS 0.00-1.00x63. Best corrected VA for OD 6/10, OS cannot be determined due to the one-month vitrectomy for treatment of macular hole and left ptosis. Both eyes had cataract surgery in the past and the patient reported severe dry eyes (Fig 1).

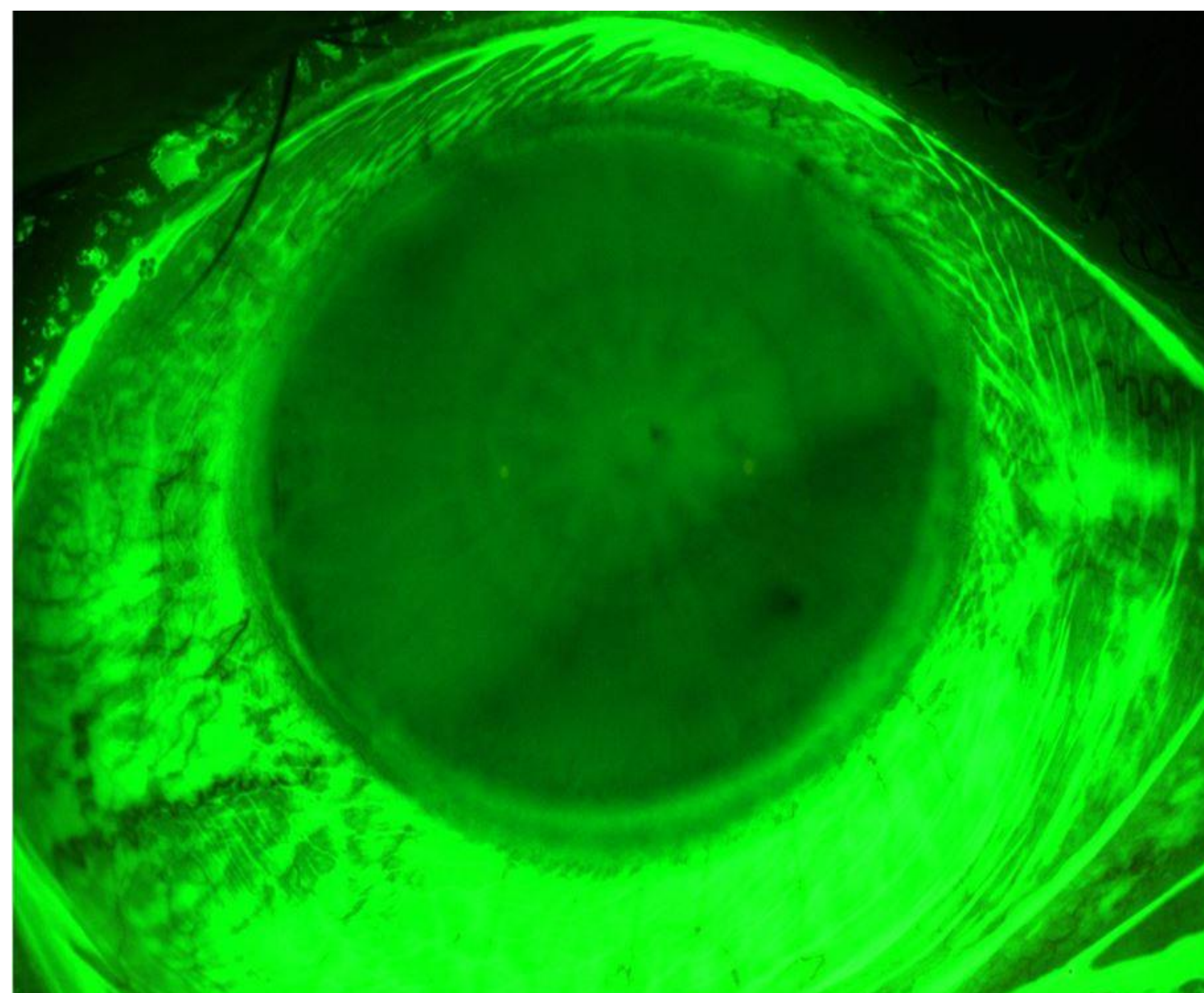


Fig 1 Slit-lamp photograph right after fluorescein instillation.

## Results

The ESP data revealed a highly irregular scleral pattern, as seen on the ESP bi-sphere elevation map (Fig 2). Due to the asymmetry and of the sclera, a customized freeform lens was designed and manufactured from the corneoscleral Profilometry.

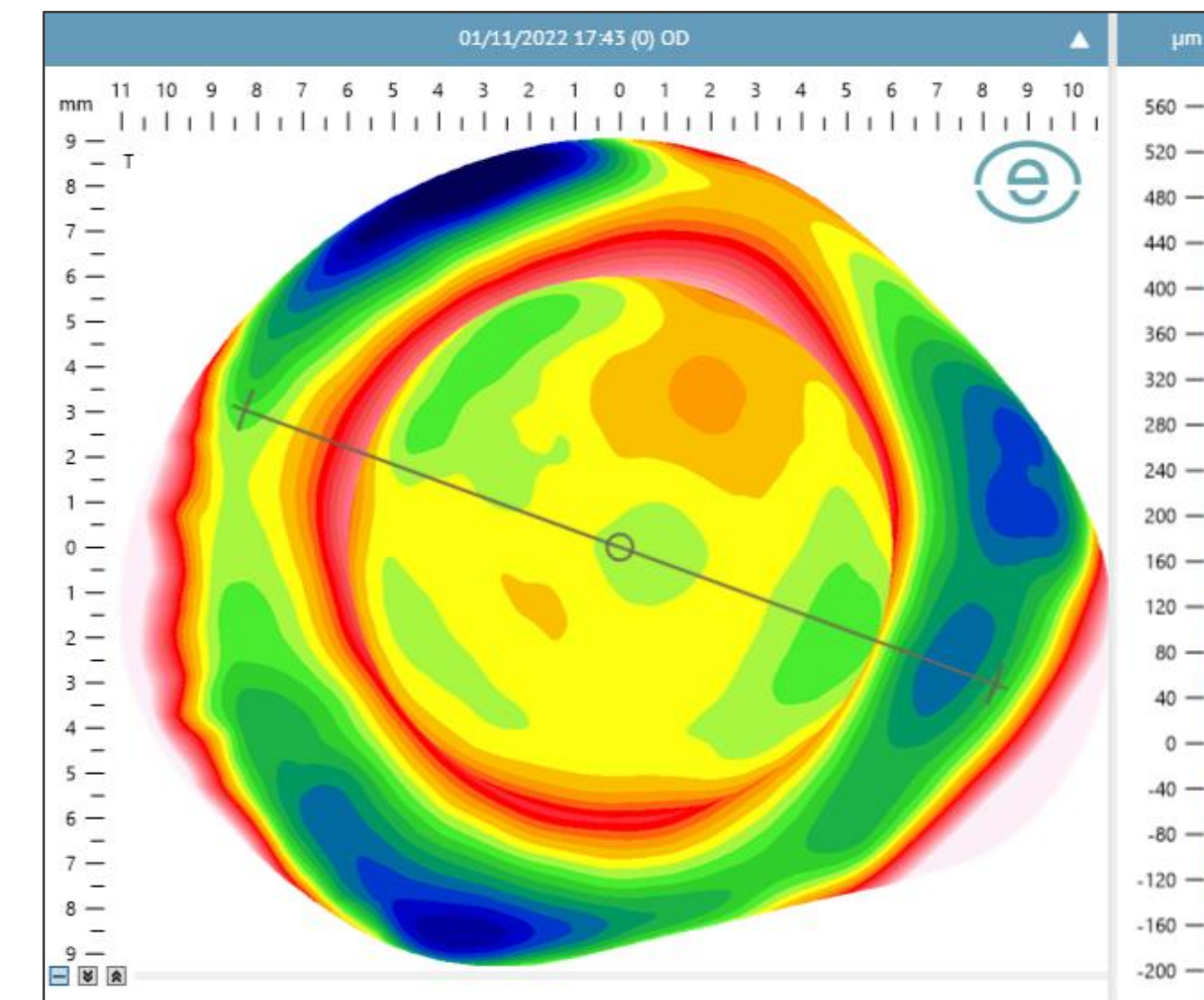


Fig 2 Bisphere elevation map by the ESP

The VA at the initial dispense was OD 9/10. The lens showed uniform clearance and the sclera did show reduced redness. The patient reported better comfort and vision with the lens (Fig 3).

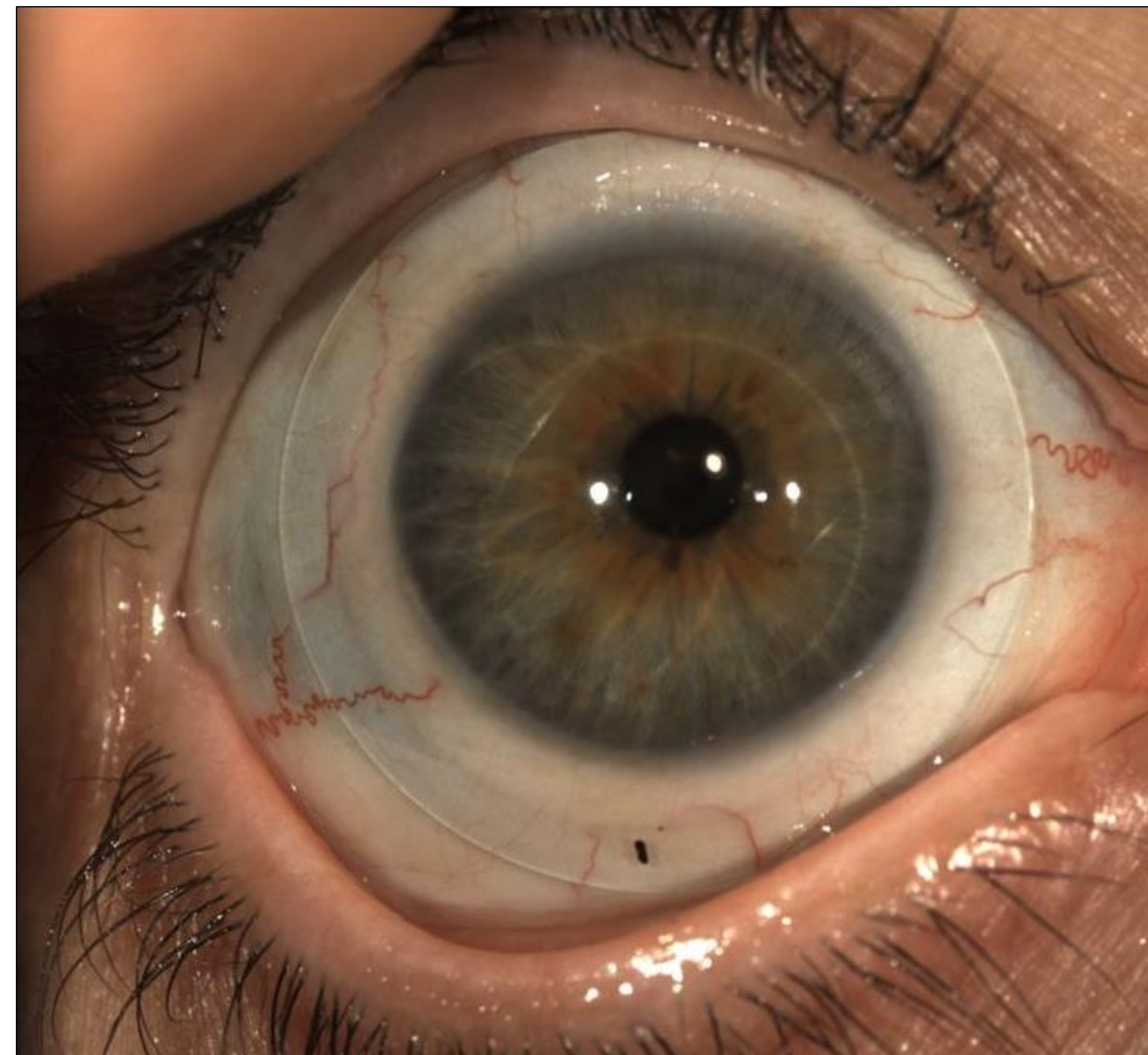

Fig 3 First and final fit

## Discussion

Profilometry and empirical contact lens fitting has number of advantages. Patients report to have a greater satisfaction with their visit due to the reduced chair time and higher first fit success. Thanks to the accurate scleral data Profilometry assists designing empirical freeform scleral contact lenses fitting precisely and it may help to reduce chair time and refits, leading to happy patients.

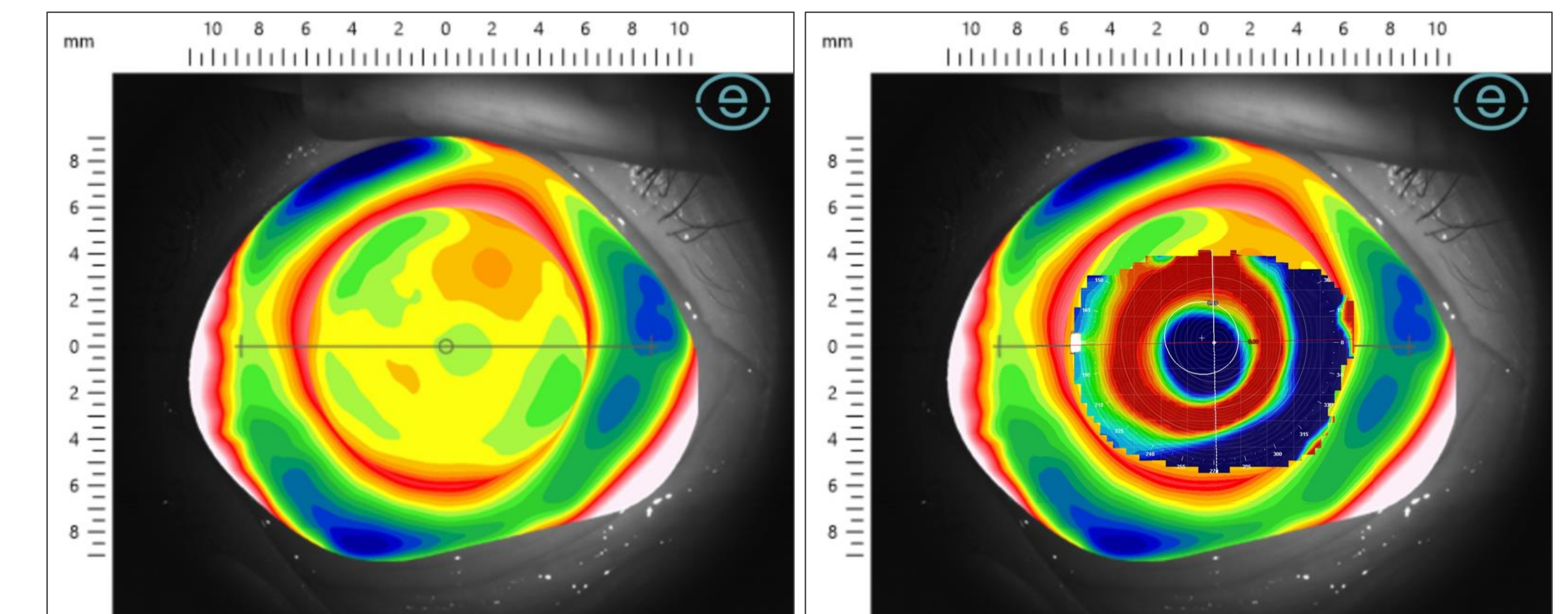


Fig 4 ESP Bisphere elevation map on source image

Fig 5 Meridia corneal map overlapped on ESP map

The images shown here show ESP corneo-scleral Profilometry data of 20mm diameter (Fig 4) and corneal topography capture with the Meridia (Medmont, Australia) of 9mm (Fig 5).

## Contact details and disclosure

Kyriakos Telamitsi,  
BSc. Optics, Optometry, Contact Lenses Practitioner.  
FSLs, ISCLS, MGPLI, MEurOK, MEAOO, MCOA, MHAO.  
Kyranto Optical Centre Ltd.  
160 Ellados Str., 3041, Limassol, Cyprus.  
Email: kamitsi001@gmail.com,

Precise Empirical Scleral contact lens fitting designing utilizing Profilometry.  
Poster EAOO Poznan, Poland on 12-14 May 2023.