

Incorporating a Bi-Elevation Design For Improved Scleral Lens Centration

Germán Aparicio, OD; Lindsay A. Sicks, OD, FAAO, FIACLE, FSLs • Illinois College of Optometry, Chicago, IL

INTRODUCTION

Inferior lens decentration is common when fitting scleral lenses in patients with keratoconus (KCN), as a greater sagittal depth is required to adequately vault the cornea. This results in a large central tear reservoir which can further decenter the lens. The inferior decentration can be further exacerbated by limbal toricity. This case highlights the use of a bi-elevation scleral lens design for improved lens centration in a patient with KCN and limbal asymmetry.

CASE HISTORY

A 17-year-old male presented for evaluation of blurry vision OU for the last few years in his habitual glasses. He had no prior h/o CL wear. In 2018, he was diagnosed with KCN OU and underwent corneal collagen cross-linking the same year.

- Manifest Refraction:
OD: -1.25-1.75x055 20/100
OS: -1.75-0.75x105 20/30
- Slit Lamp: central corneal steepening and thinning OU, (+) Vogt striae OU
- Corneal tomography confirmed bilateral KCN (Figure 1).

CONTACT LENS EXAMINATION

The patient was fitted in a 16.0mm Zenlens scleral (Bausch + Lomb Specialty Vision Products) which improved vision to 20/25 OD and 20/20 OS.

At a 2-week follow-up visit, the patient reported mild discomfort with lens wear. Inferior lens decentration was noted OU along with 1+ punctate staining at the superior limbus OU. Scleral profilometry revealed limbal toricity of 250um OD and 270um OS (Figure 2). To improve lens centration, a new pair of lenses was ordered which incorporated a bi-elevation design. Improved lens centration was noted at the time of dispense.

At a 1-week follow-up visit, the patient reported wearing lenses 15 hours a day with excellent comfort OU and the superior limbal PEE had resolved OU (Figure 3).

FIGURE 1
Tomography showing anterior and posterior corneal steepening OU.

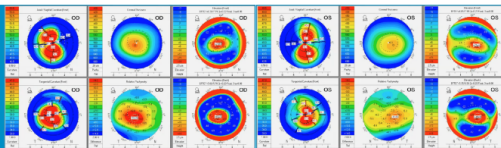
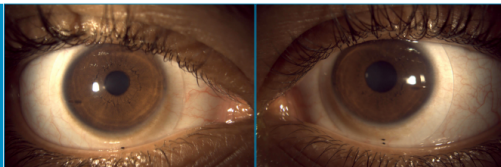


FIGURE 2
Profilometry displaying toricity of 250 microns OD and 270 microns OS at a 12-mm chord length.

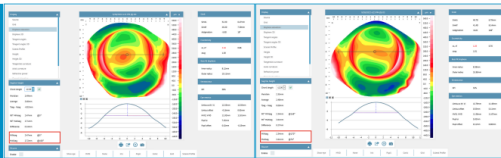

FIGURE 3
At a 1-week follow up visit, the patient reported excellent comfort when wearing scleral lenses OU and the superior limbal PEE had resolved OU.



DISCUSSION

Scleral lens centration is influenced by several factors including the corneal sagittal height, limbal shape, and scleral shape. All these factors can be assessed using corneal and scleral profilometry and should be taken into consideration to obtain an optimal scleral lens fit.

The Zenlens' bi-elevation design moves some of the advanced peripheral system (APS) toricity into the vault chamber. This widens the landing zone surface area, allowing the deeper, steeper meridian APS to land closer to the limbus, improving lens centration.

CONCLUSION

One major challenge to fitting a scleral lens is achieving proper centration. Decentration can result in an excessive fluid reservoir that could interfere with corneal physiology. A common reason for inferotemporal decentration is related to limbal shape and elevation. The limbus is often wider horizontally than vertically, and elevation differences also exist. Profilometry can highlight the need for a quadrant-specific limbal (bi-elevation) design upfront, improving overall centration of the first lens fit.

REFERENCES

1. Macedo-de-Araújo RJ, Amorim-de-Sousa A, Queirós A, van der Worp E, González-Méjome JM. Relationship of placido corneal topography data with scleral lens fitting parameters. *Cont Lens Anterior Eye*. 2019 Feb;42(1):20-27.
2. Consejo A, Llorens-Quintana C, Radhakrishnan H, Iskander DR. Mean shape of the human limbus. *J Cataract Refract Surg*. 2017 May;43(5):667-672.
3. Fadel D. The influence of limbal and scleral shape on scleral lens design. *Cont Lens Anterior Eye*. 2018 Aug;41(4):321-328.

CONTACT INFORMATION

Germán Aparicio, OD
gaparicio@ico.edu
www.ico.edu