

Case Report:

Scleral MicroVault

Kyriakos Telamitsi

Kyriakos Telamitsi is an experienced contact lens practitioner working in Limasol (Cyprus). Next to fitting medical devices is maintaining his own practice the Kyranto Optical Center.



Introduction

A 35 years old male used to wear RGP contact lenses. Working in a dusty environment caused irritation. He is diagnosed with mild keratoconus resulting in sensitive dry eyes which makes him incapable of wearing his RGP's anymore. Scleral lenses are advised although a pinguecula is often a contra-indication choosing a scleral lens. This is due to a risk of irritation.

Examination

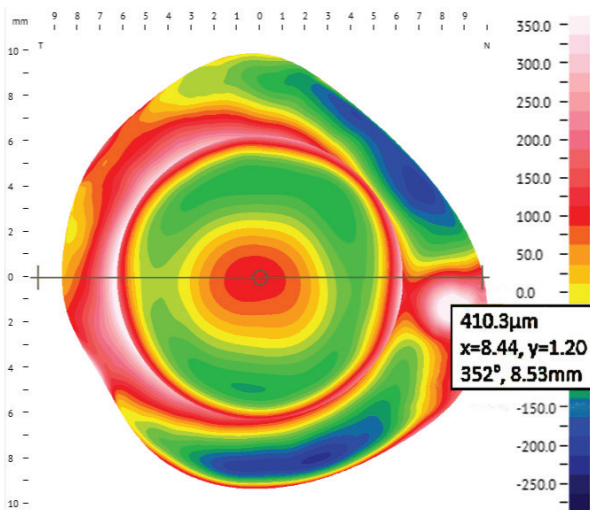


Figure 1

Corneoscleral Profliometry measurement shows an eye with a central cone (see central red elevation, Figure 1) and a nasal pinguecula with a local elevation of 410microns at the highest point. The measurement of 410 microns has been taken 8.44mm away from the Apex, Since we are using 17mm prolate Zenlens we can predict that the edge of the lens is touching the pinguecula.

Scleral lens ordered is a 17 diameter Prolate Zenlens design: 4900, 7.80, S-1.25, Flat4/Steep0, flat axis stabilizer 178, MicroVault nasal axis 356, decentration 8.5mm, width 3.5 mm and depth 350 microns.

Conclusion

A scleral lens with a MicroVault was used to bypass irritation which can be induced by the pinguecula (see Figure 2). Patient is happy with the lenses and able to wear them during worktime which he was not able to do with the RGP's. He takes the lenses out after he get's home. When necessary he re-installs the lenses after a short break.

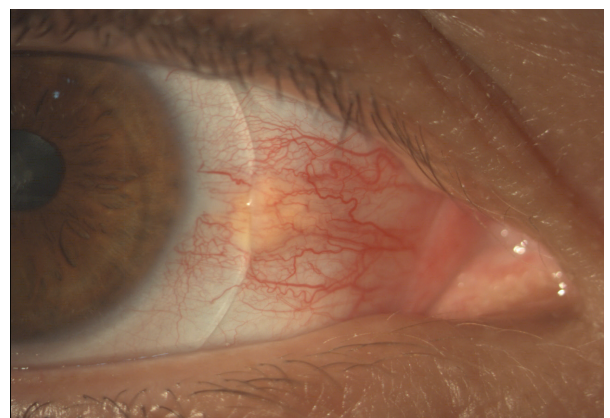

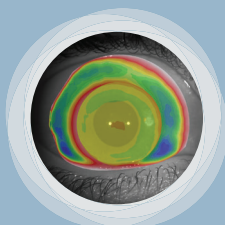
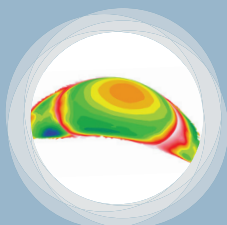
Figure 2



eaglet-eye

Case Report

Scleral Microvault



— Find us online

 @eagleteye

 /eagleteye

— Make contact

 +31 6 23 941 643

 info@eaglet-eye.com

eaglet-eye.com